

Lumen Shape: A New Measurement to Consider in the Treatment of Iliofemoral Venous Outflow Obstruction

Exploring the role of pre- and postprocedure lumen shape in predicting patient outcomes.

BY MICHAEL K.W. LICHTENBERG, MD, FESC

With the advent of dedicated venous stents, physicians no longer have to rely on the use of repurposed arterial or general utility stents in the treatment of venous outflow obstruction (VOO). This is significant because of the differences in the anatomy of veins versus arteries as well as the etiology of the disease addressed in the treatment of VOO. To a far greater degree than ever before, the external compression of the nonthrombotic iliac vein lesion is recognized in cases of deep vein thrombosis and chronic venous disease with clinical, etiology, anatomy, and pathophysiology (CEAP) classification clinical scores C4 to C6.¹ Additionally, the restriction of the elastic collagen bands found in the postthrombotic iliofemoral vein segments present unique challenges for balloon angioplasty and stenting.²

The ideal dedicated venous stent will comprise a balance of design features that address the needs of physicians treating VOO. These design features will include open- versus closed-cell architecture, radial strength, coverage, flexibility, ease of use, and accuracy of placement. There are currently six dedicated venous stents with CE Mark approval and four with US Food and Drug Administration investigational device exemptions (IDEs) for clinical studies being conducted at centers in the United States, Europe, and Australia.

The question remains, how do we measure the performance of these stents in the treatment of venous disorders? Clinical trials present data on safety and efficacy, but efficacy is generally limited to stent patency. Ongoing debate about the degree of stenosis and severity of venous disease at which patients should be treated for VOO calls into question patency as a singular measure of stent performance. It is important to know what performance characteristics of dedicated venous stents contribute to improved clinical success.

FLUID DYNAMICS AND LUMEN SHAPE

Raju et al have provided significant insight into area as a proxy for determining success in venous stenting in the ilio-

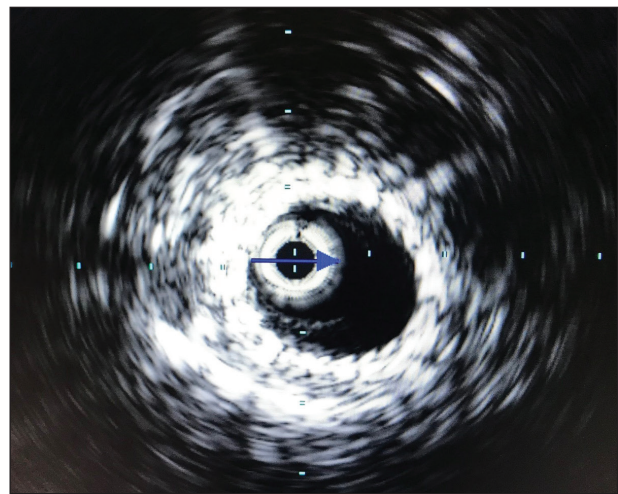


Figure 1. Postprocedure IVUS image of a 41-year-old woman with postthrombotic obstruction. The round lumen shape suggests a lower and improved aspect ratio.

femoral veins. Stents implanted in the iliofemoral veins are subjected to both external compressions at anatomic choke points and/or recurrent postthrombotic stenosis. Increases in area should result in greater flow volume and reduced peripheral venous pressure.³

The ability to predict patient outcomes through assessment of stenosis using different imaging modalities has also been recently published. Gagne et al found that a threshold stenosis of 54% was optimal to indicate stenting in VOO and correlated with future clinical improvement. The threshold was higher in the subset of nonthrombotic patients (61%).⁴

Can the theoretical science of fluid dynamics on flow rate, volume, and pressure be applied to stenting of VOO in the treatment of venous disease? There may be other technical performance characteristics of venous stents that require investigation as we seek to better understand the relationship between stent performance and patient outcomes.

Lumen shape is defined by aspect ratio. For a vein, this is expressed as a ratio of maximum diameter to minimum

diameter. A perfect circle has an aspect ratio of 1. Figure 1 shows an IVUS image of a vein poststenting with a round lumen, suggesting a lower and improved aspect ratio. As the ovality of the vein increases, so does the aspect ratio.

When a perimeter is held constant, the area is dramatically different for various shapes, from a perfect circle to a dramatic oval. Figure 2 demonstrates the theoretical changes in flow as a shape with the same perimeter increases in aspect ratio and ovality.⁵ Flow volume is dramatically reduced with an increase in ovality. The science also demonstrates that, in order to maintain the same flow rate, an increase in pressure would be required to overcome the resistance in flow due to the flatter shape.

Fluid dynamics suggest that shape matters, as it directly affects the area for a given perimeter. Furthermore, the theory of hydraulic diameter implies that shape will have an effect on the cross-sectional flow area (hydraulic diameter is the effective flow diameter for a nonround shape; for a circle, it is the diameter). This will then have an impact on flow and pressure. Applying these concepts in clinical practice and analyzing the outcomes may provide clinicians with valuable information that could have an impact on long-term clinical success. This research is intended to explore the relationship of changes in venous cross-sectional area (CSA) and lumen shape postindex procedure to patient outcomes at 12-month follow-up.

METHODS

The VIRTUS investigational device exemption trial (NCT02112877) of the Vici Venous Stent® System (Veniti, Inc.) included a 30-subject feasibility cohort that was conducted at nine centers in the United States and Europe. Patients aged 18 years and older with clinically significant venous obstruction (eg, luminal diameter reduction $\geq 50\%$) were eligible. Included patients presented with a CEAP classification clinical score ≥ 3 or Venous Clinical Severity Score (VCSS) pain score ≥ 2 . Major exclusion criteria were pulmonary emboli within 6 months of enrollment, contralateral venous disease, obstruction extending into the inferior vena cava, active coagulopathy, and intended concurrent venous procedure within 30 days of index procedure.

Notably, the VIRTUS trial included the use of duplex ultrasound, multiplanar venography, and intravascular ultrasound (IVUS); all were reviewed in a core lab. For the purpose of this analysis, the focus was on eight IVUS measurements of the common iliac vein (proximal, central, and

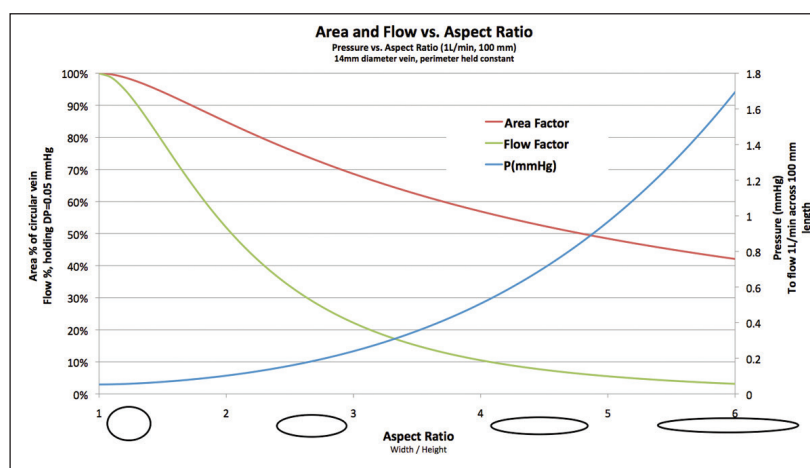


Figure 2. Holding perimeter constant, as the aspect ratio (ovality) increases, the area decreases. To maintain the same flow rate, pressure must increase.

distal), external iliac vein (proximal, central, and distal), and common femoral vein (proximal and distal) made at both baseline and postprocedure. From these measurements, median changes in CSA and lumen shape, as defined by aspect ratio, resulting from stent implantation were calculated.

VCSS scores were used as the clinical assessment metric in the lumen shape analysis. VCSS scores were captured in the VIRTUS trial at baseline, 6, and 12 months. Specifically, the change in VCSS from baseline assessment to 12 months was used in the analysis of the relationship of changes in CSA and lumen shape to clinical outcomes.

Pearson correlation coefficients (r) measured the strength of the relationship between the following pairs of variables: poststent change in CSA and 12-month VCSS score and poststent change in aspect ratio and 12-month VCSS score.

RESULTS

The 30-patient feasibility cohort was composed of 24 women and six men with a median age of 43 years. The mix of lesion etiology was 19 (63%) postthrombotic and 11 (36%) nonthrombotic; 25 (83%) were left leg lesions. Fifteen patients had lesions involving more than one vein, including nine with involvement of the common iliac, exter-

TABLE 1. ANATOMIC CHANGES IN CSA AND ASPECT RATIO

	Prestent	Poststent	Pre- to poststent change
CSA, cm ² (range)	43 (20 to 76)	130 (73 to 286)	74% (-18% to 48%)
Aspect ratio (range)	2.8 (1.2 to 5.3)	1.3 (1.1 to 2.2)	-45% (-77% to -0.2%)
Abbreviations: CSA, cross-sectional area.			

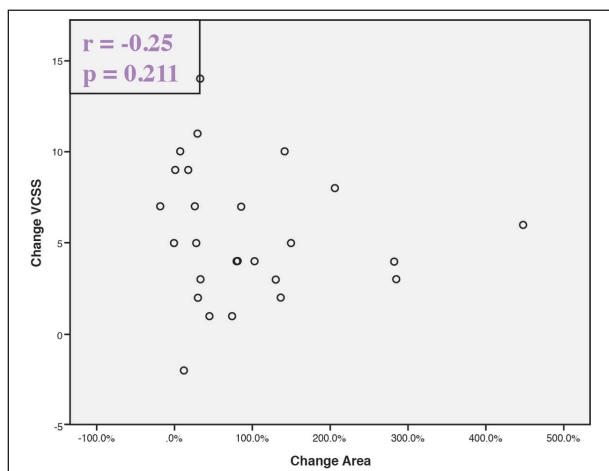


Figure 3. Postprocedure CSA increases from left to right on the x-axis. There was no relationship between increase in postprocedure CSA and clinical improvement.

nal iliac, and common femoral veins. Median baseline stenosis was 91% (range, 50%–100%).

The anatomic changes in CSA and aspect ratio, pre- and poststenting, are presented in Table 1. Twenty-seven patients with available 12-month VCSS scores were utilized for this analysis. Three patients were outside the 12-month follow-up window 365 ± 60 days. Median VCSS score declined by 5 points from baseline to 12 months, and 23 (85%) patients experienced symptomatic improvement (≥ 2 -point score improvement).

The change in area from pre- to postprocedure was calculated for each patient, using the formula: (postprocedure area - baseline area)/baseline area. Looking at patients' changes in vessel area from baseline to postprocedure, one would expect to see a positive correlation between area change and clinical improvement; that is, the greater the relative increase in luminal area, the greater the clinical improvement. However, as Figure 3 shows, this was not observed. The correlation coefficient between these variables ($r = -.25$) indicates a negative relationship between the variables, which is surprising but should not be attributed any significance considering the strength of the relationship. At $-.25$, this correlation coefficient does not even meet the threshold of a weak relationship. This is a negligible relationship, and as shown in Figure 3, there is no clear pattern. This is also confirmed by the P value of .211.

Conversely, in Figure 4, there is a clearer relationship in the correlation between postprocedural change in lumen shape and clinical improvement. Analysis showed a moderately positive relationship ($r = .50$) between the decreased ellipticity of the stented vessel and clinical improvement. Patients undergoing the greatest luminal change in the direction of oval to round are most likely to exhibit clinical

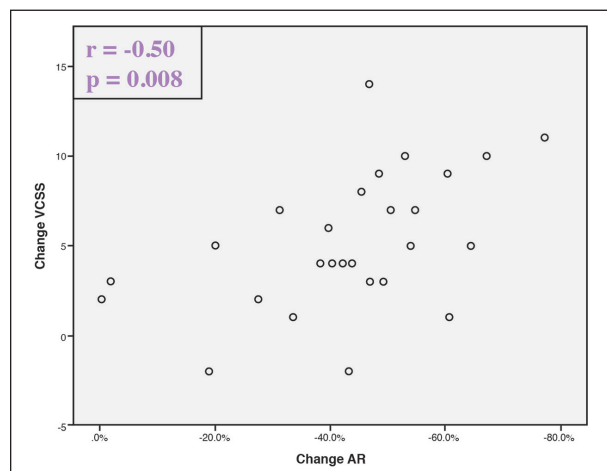


Figure 4. Postprocedure aspect ratio improves (lower value) from left to right on the x-axis. A moderately positive relationship between lower aspect ratio and clinical improvement is seen and is statistically significant.

cal improvement, which is a statistically significant finding ($P = .008$).

CONCLUSION

This research suggests that increased poststenting CSA is desirable, and change in lumen shape, as defined by aspect ratio, may contribute further to positive patient outcomes. Additionally, with further research, aspect ratio may be important as a predictive factor of clinical improvement in patients treated for VOO. Further research is necessary and forthcoming. Validation of this analysis with the VIRTUS trial 170-patient pivotal cohort is required. ■

Acknowledgment: The author thanks Dana Bentley (Syntactx) for statistical analysis for this article.

1. Raju S, Neglen P. High prevalence of nonthrombotic iliac vein lesions in chronic venous disease: a permissive role in pathogenicity. *J Vasc Surg*. 2006;44:136–144.
2. Jalaie H, Schleimer K, Barbat ME, et al. Interventional treatment of postthrombotic syndrome. *Gefasschirurgie*. 2016;21(suppl 2):37–44.
3. Raju S. Ten lessons learned in iliac venous stenting. *Endovasc Today*. 2016;15:40–44.
4. Gagne PJ, Gasparis A, Black S, et al. Analysis of threshold stenosis by multiplanar venogram and intravascular ultrasound examination for predicting clinical improvement after iliofemoral vein stenting in the VIDIO trial. *J Vasc Surg Venous Lymphat Disord*. 2018;6:48–56.
5. Schifflette JM. Analytical overview of fluid dynamics science related to venous iliofemoral blood flow and vessel shape. 2017. Internal Veniti, Inc. report; unpublished.

Michael K.W. Lichtenberg, MD, FESC

Angiology Department/Venous Centre
Klinikum Arnsberg
Arnsberg, Germany
klichte@gmx.net

Disclosures: Receives speaker honoraria from Veniti, Inc., C.R. Bard GmbH, OptiMed GmbH, and ab medica GmbH.